Scan Now!

Innovative Ophthalmology Solutions

NEW

5-in-1 System for Faster and Deeper Diagnosis
3D OCT, Angiography, Fundus Camera, Biometry, Topography

OCTavius

Huvitz CONNECTING SIGHT SUCCESS

5 in 1
OCTavius

The accuracy you can see!

Diagnose Faster and More Accurately with OCTavius.
Combining five critical ophthalmic functions into a single platform, OCTavius enhances patient comfort and streamlines clinical workflow.

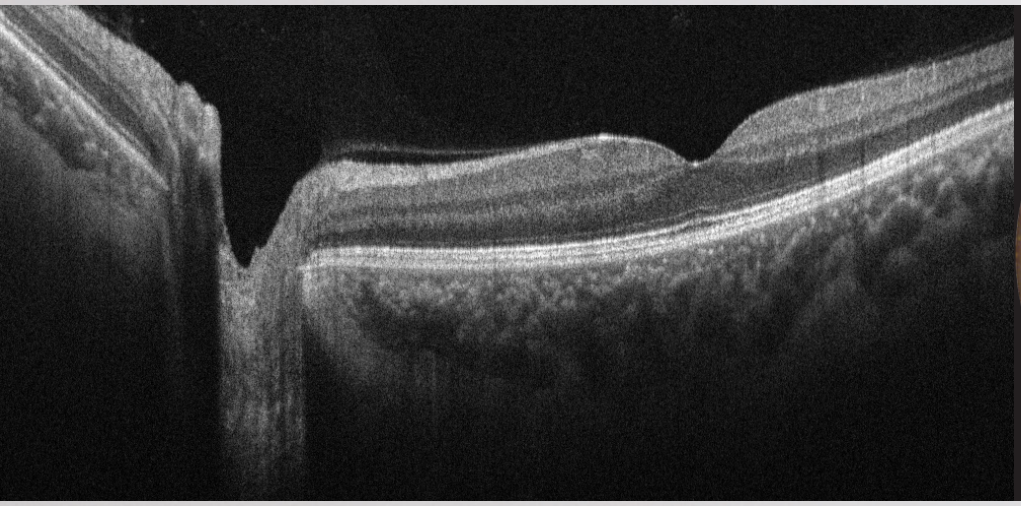

3D OCT

High-speed 12mm wide scan,
High-resolution, Detailed tomography

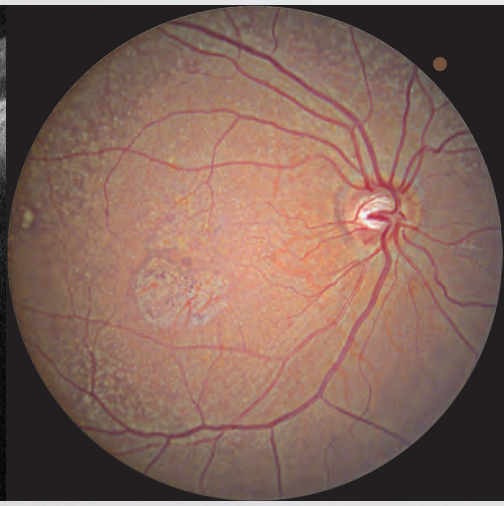

Fundus camera

Accurate lesion detection
Widefield panoramic image

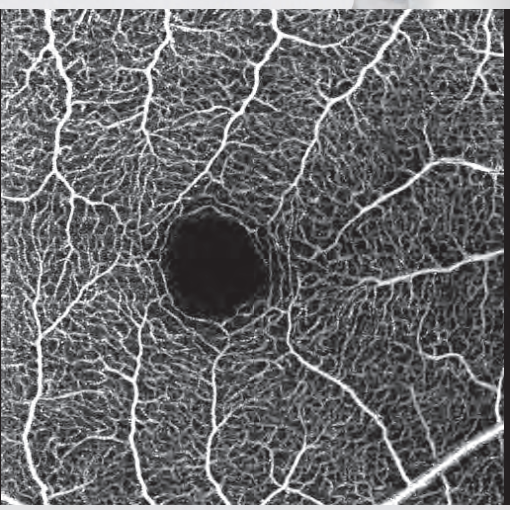

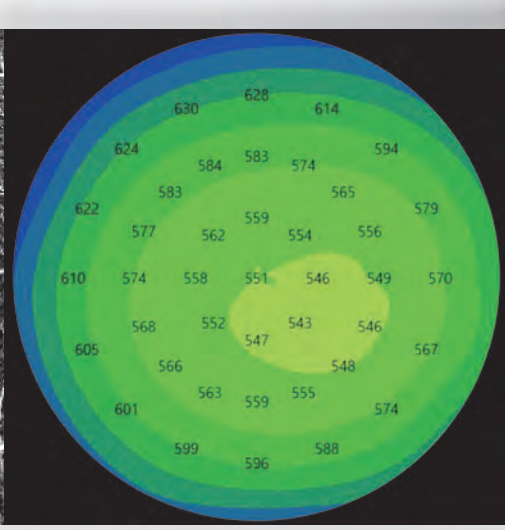

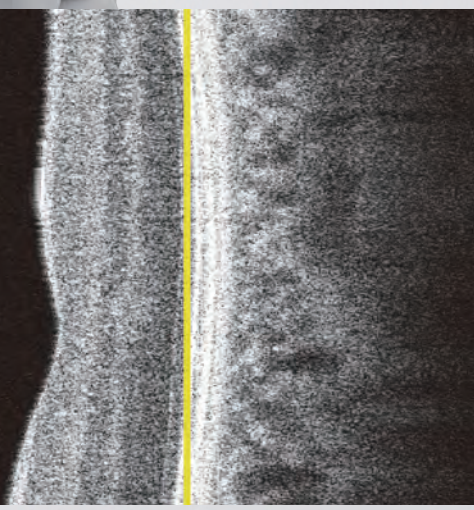

Angiography

Fast scanning & Precise detection
Wide imaging & Mosaic imaging

Topography

16 maps including pachymetry
Comprehensive analysis

Biometry

Fast acquisition in the Burst mode
The data is reviewable and editable

3D OCT

Fast, Clear Imaging for Retinal Care

Obtain precise 3D images of the retina and macula in under one second.
High-resolution scans enable detailed layer-by-layer analysis, enhancing the reliability of early diagnosis and clinical decision-making.

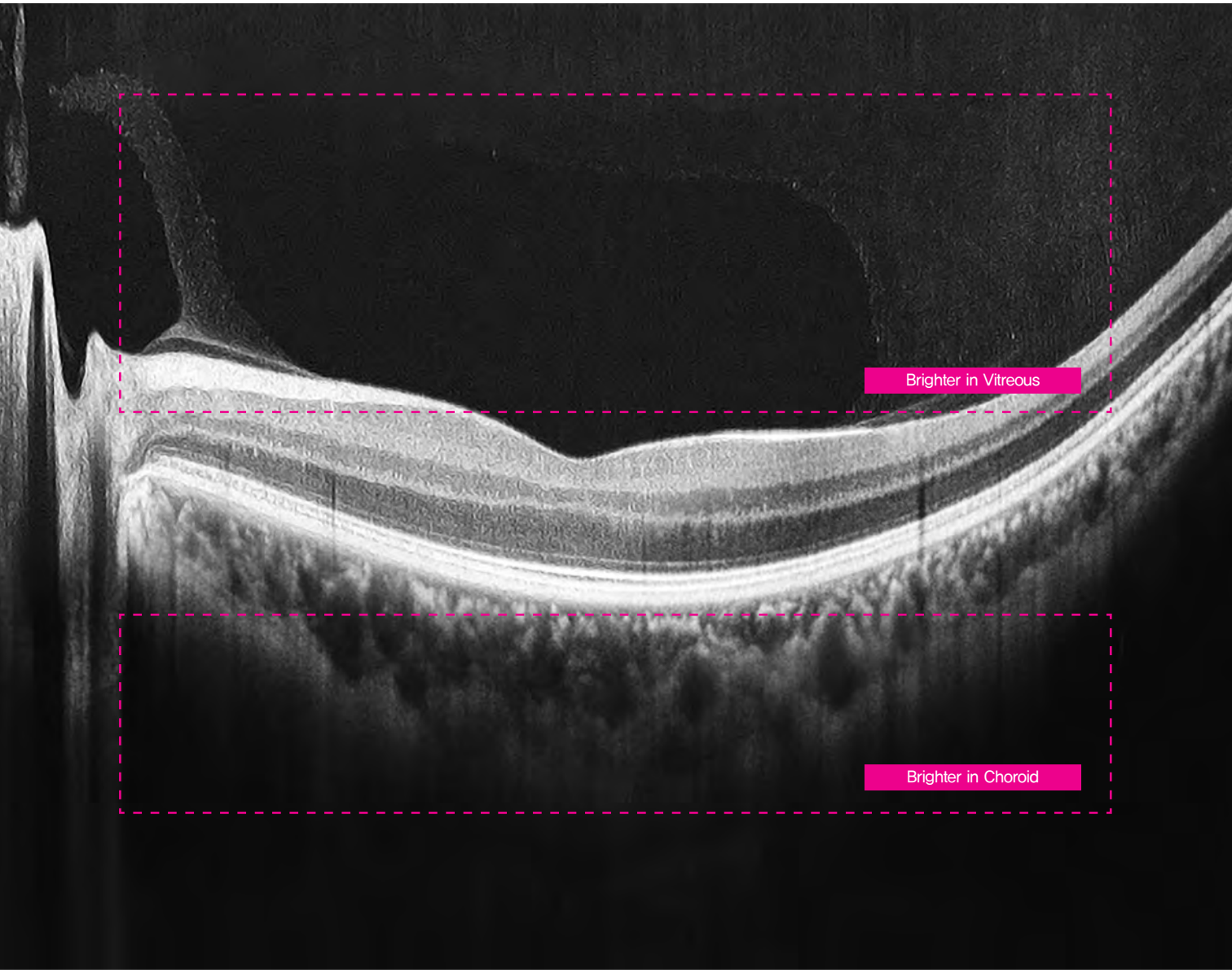

12mm macular line overlap 30, ECI mode, Huvitz

Accurately capture the retina and choroid with high-resolution scans

Fast and stable scanning technology allows precise visualization of the fine structures of the retina and choroid. It is effective for diagnosing various major ophthalmic diseases such as retinal detachment and vitreous opacity. In ECI(Enhanced Choroidal Imaging) mode, depth signals are inverted to maximize choroidal layer contrast.

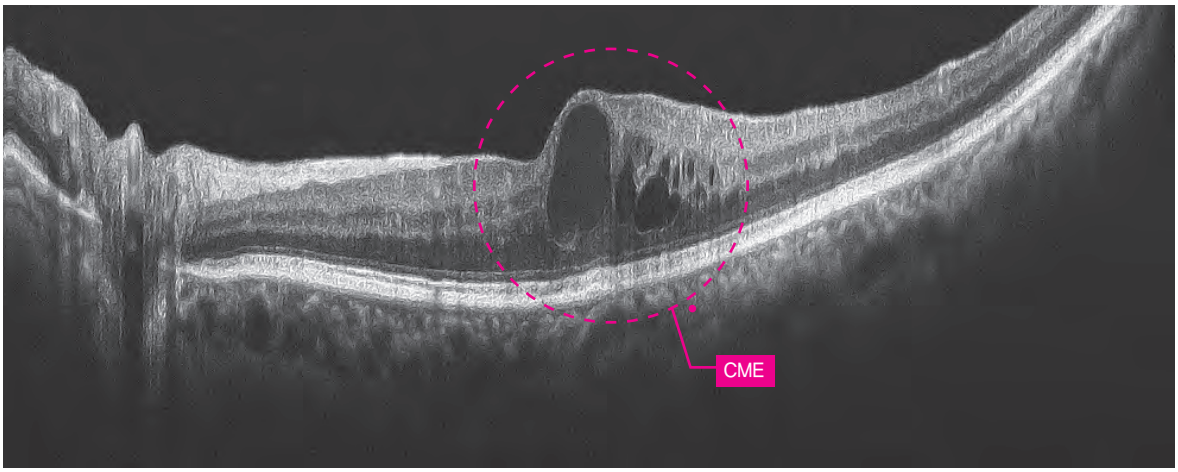

12mm macular line overlap 30

Precisely capture even microstructural changes

Morphological abnormalities such as cystoid macular edema(CME) and dome-shaped elevations can be clearly identified, and early detachment of the RPE layer can also be distinguished, enabling early assessment of lesion progression.

Clinical Insight	Early detection of CME lesion structure and progression stage.

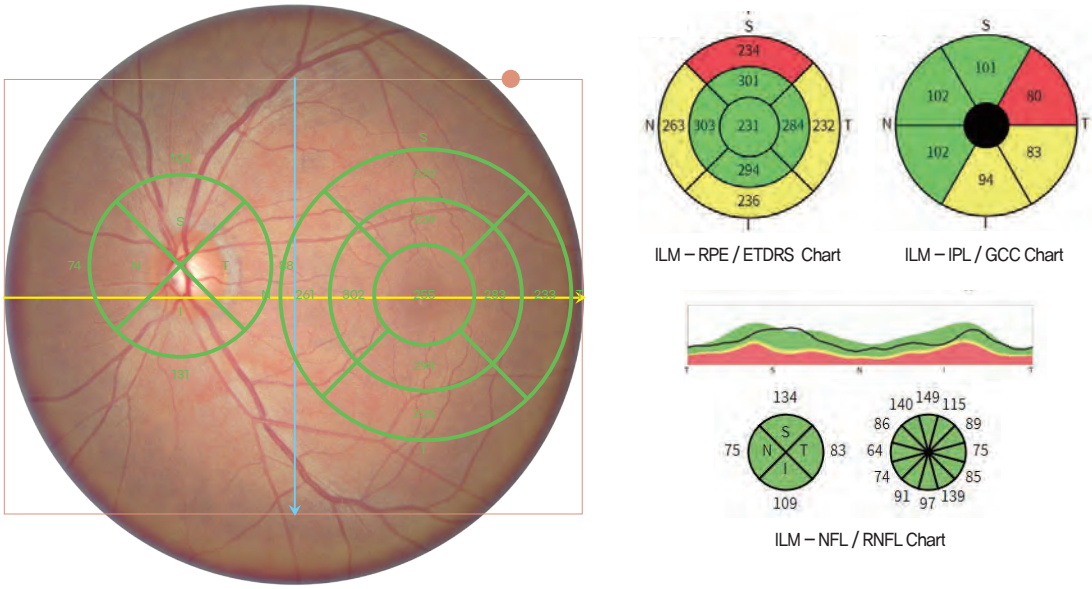

12mm macular wide overlap 10,Huvitz

Simultaneous scanning of the retina and optic nerve head

A single 3D scan captures both the retina and the optic nerve head, providing various analysis metrics, such as the ETDRS Chart, Ganglion Cell Chart, RNFL Chart, and TSNIT Chart. This enables the precise analysis of structural changes in the optic nerve head and supports early diagnosis of optic nerve-related diseases, such as glaucoma.

Clinical Insight	Simultaneous assessment of retinal and glaucoma indicators for enhanced diagnostic efficiency.

Fundus

True Color Fundus in One Shot

Huvitz's proprietary image processing technology, Smart Viewing Technology(SVT), is based on the speckle noise reduction system and pre-acquisition algorithm to produce true-color images. This allows wide-ranging visualization of lesion location and extent without distortion, effectively supporting precise diagnosis and analysis.

Fundus single macular level 4, Dankook University

Capture the finest retinal microvasculature with uncompromised detail

By applying 12-bit color depth and Gamma correction technology, true-color fundus images are captured in a single shot. Brightness distribution is flattened to evenly represent both the dark retina and the bright optic nerve head, clearly visualizing arteries, veins, and even microvasculature. This enables accurate fundus image analysis without color distortion, enhancing diagnostic reliability.

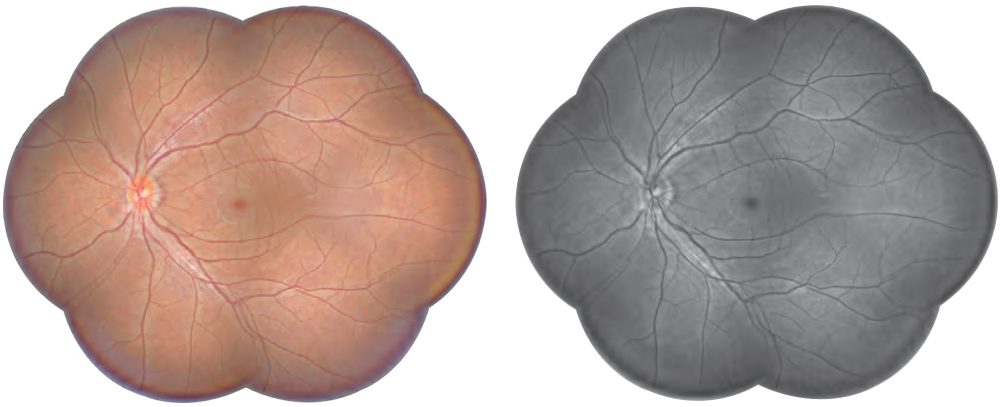

Fundus panorama level 4/Grey, Huvitz

Wide-angle panorama view effective for lesion monitoring

A wide-angle panorama view effective for lesion monitoring is generated using between 2 and 7 fundus images. The wide-range fundus structure can be viewed in a single image, allowing for more intuitive identification of the location and extent of lesions such as diabetic retinopathy.

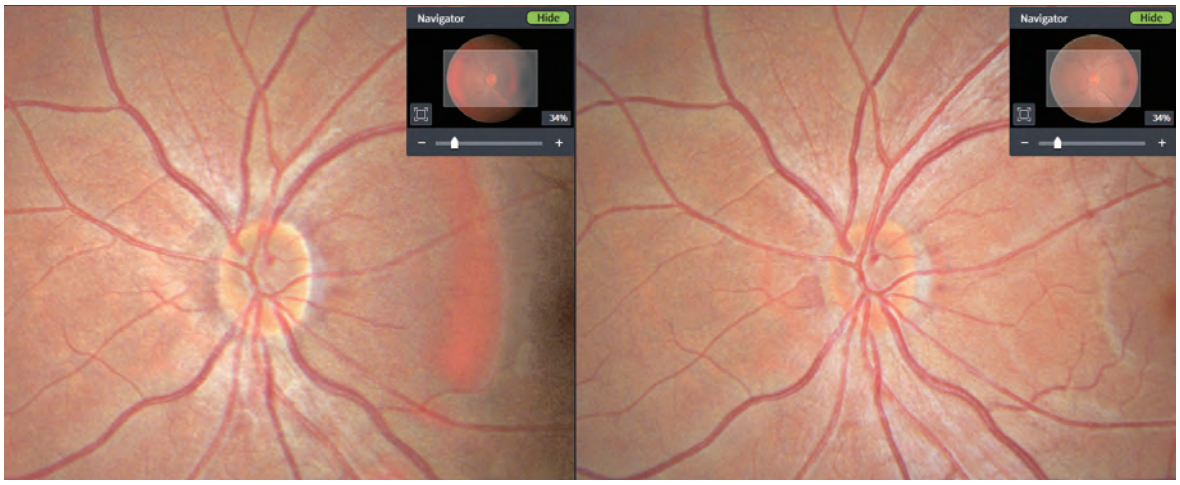

Fundus disc stereo in HIIS-1, level 4, Huvitz

Structural analysis of the optic nerve head

The patient's optic nerve head is measured from different left and right viewpoints to accurately analyze structural damage to the optic nerve head.

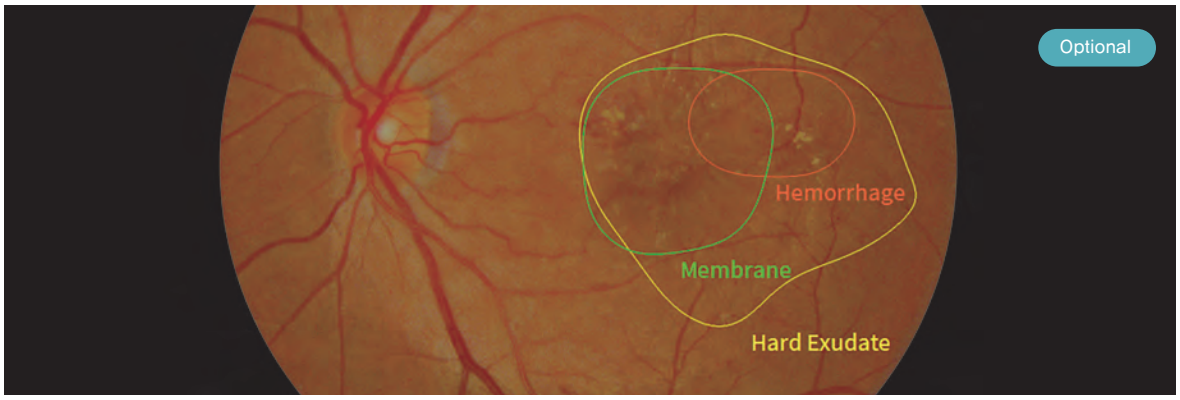

Fundus single macular, level 1, VUNO AI image

Analysis of 12 lesions using AI

The AI-based fundus analyzer divides the retina into eight regions, analyzes 12 lesions, and accurately indicates their locations.

Advanced Fundus Imaging

Users can select the desired brightness and color tone of the fundus images according to their diagnostic style, enhancing clinical convenience.

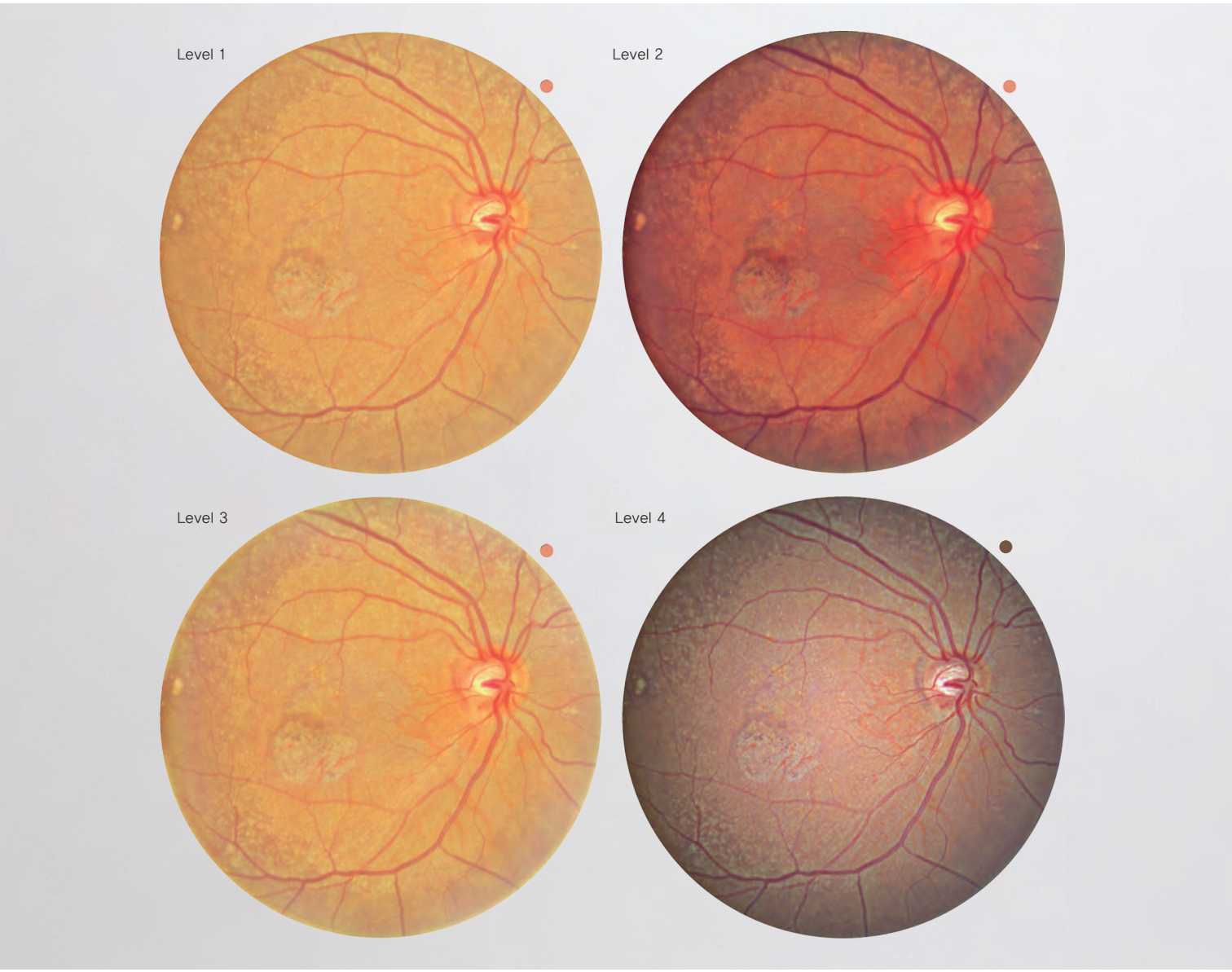

AMD, Fundus single macular level 1~4, Dankook University

User-selected fundus color mode

Four types of fundus color images are provided, allowing users to choose the optimal color tone according to their diagnostic style or visual preference for precise observation of blood vessels.

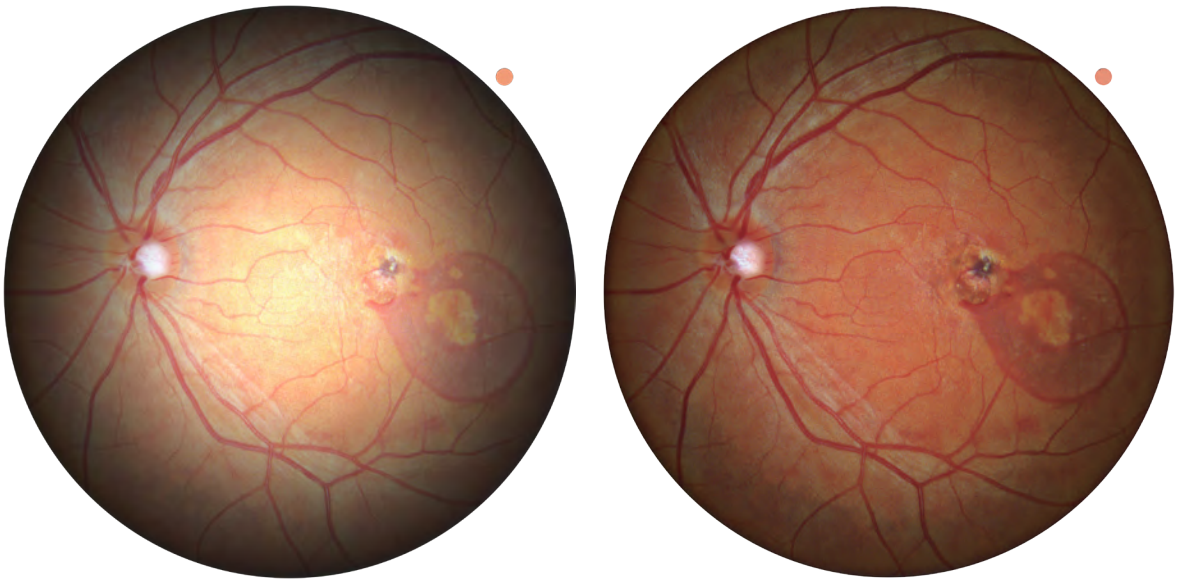

Complicated macular hole with AMD, Fundus single macular level 4, Dankook University(with updated Central BR options applied)

Enhanced lesion visibility through brightness and color adjustment

By adjusting the Central BR and Gamma values, the brightness and color of the fundus image can be finely tuned. This allows users to observe specific areas where lesions are located more clearly.

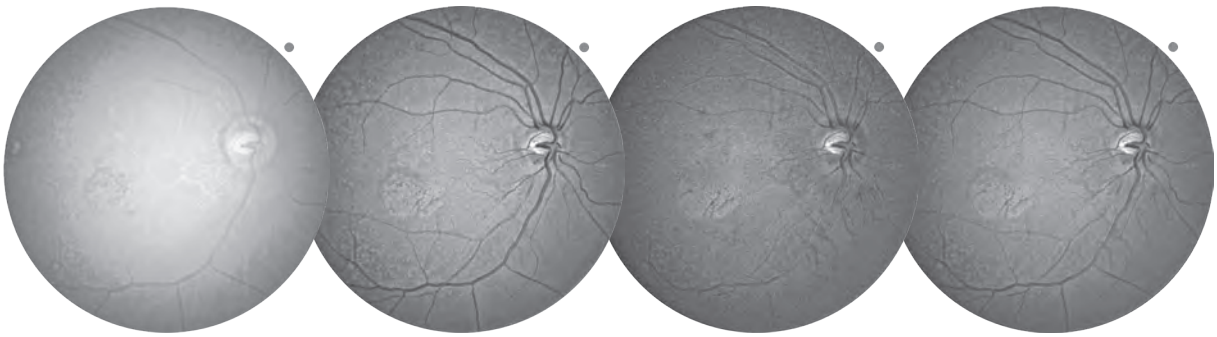

R G B Red-free

Fundus single macular level 4, Dankook University(R/G/B Channel Mode)

RGB color channels are available depending on the lesion

Users can select the R(Red), G(Green), or B(Blue) color channels to focus on lesions in the desired color.

Clinical Insight	**R Channel :** Used to observe structures reaching deep retinal layers and the choroid (analyzes deep retinal vessels, choroidal abnormalities, and hemorrhagic lesions) **G Channel :** Used to express contrast of superficial vessels and the nerve fiber layer (diagnoses vascular changes such as retinal edema, microhemorrhages, and neovascularization) **B Channel :** Used to visualize fine structures of the retinal surface and nerve fiber layer (aids in the early diagnosis of nerve fiber layer damage, such as glaucoma) **Red-Free :** Detailed visualization of retinal vasculature, RNFL, and microhemorrhage

Angiography

Fast OCT-A Imaging, Full Coverage

Wide-field mosaic imaging enables the simultaneous observation of central and peripheral lesions, making it an effective tool for diagnosing micro-lesions.

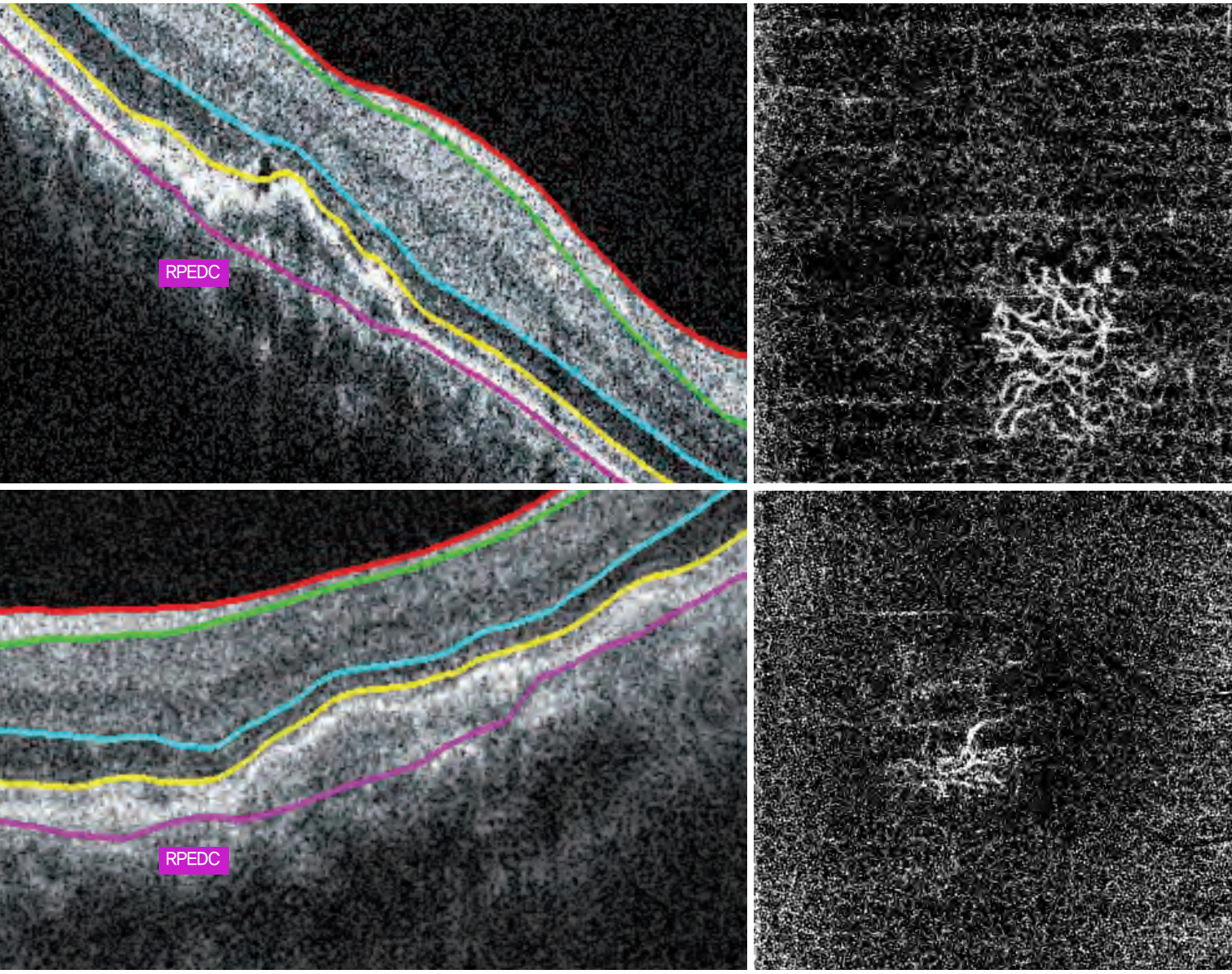

Macular angio 384x384, overlap 3, 4.5x4.5mm, outer, Dankook University, Condition: CNV

Improved CNV diagnosis clarity through precise RPE layer segmentation

The RPEDC(RPE-Drusen Complex) layer is precisely segmented to effectively eliminate speckle noise caused by RPE reflections, allowing more precise visualization of the contours of the choroidal neovascularization(CNV) area. Additionally, by utilizing the Progression function, lesion changes over time can be tracked, enabling comprehensive assessment of treatment response and prognosis, thereby enhancing diagnostic confidence.

Clinical Insight Monitoring CNV progression by stage and evaluating treatment effectiveness.

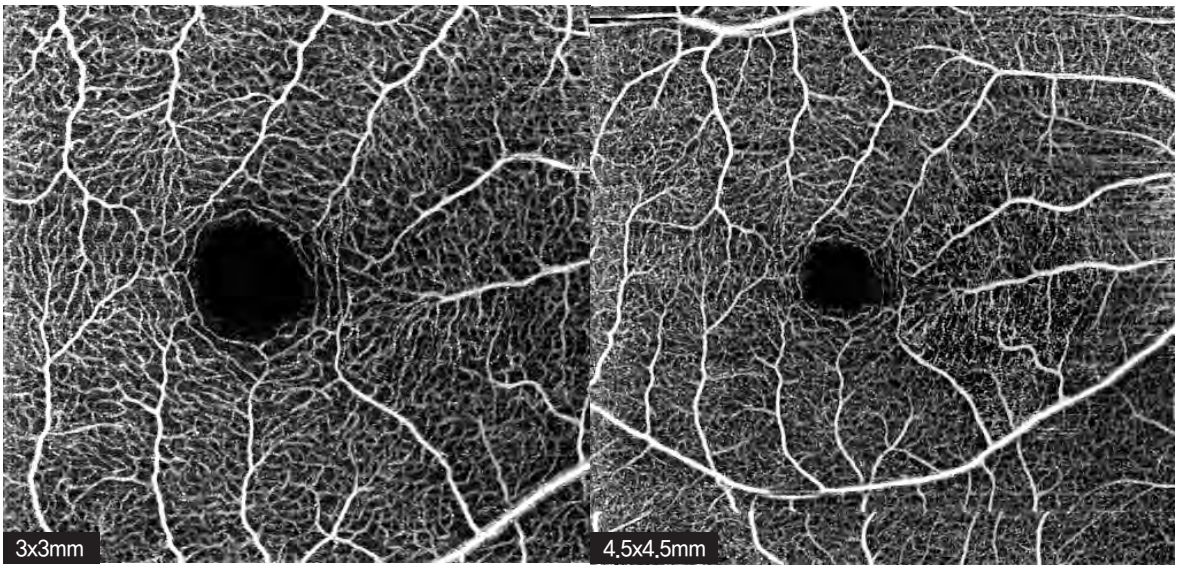

Macular angio 512x512, overlap 3, 3x3mm(left) 4.5x4.5mm(right), superficial, Huvitz

From wide to localized, detailed visualization of microvascular structures

Supporting vascular maps in various sizes—3×3, 4.5×4.5, 6×6, and 9×9 mm^2—allows flexible imaging ranging from broad coverage to localized, precise diagnosis, depending on the lesion's location and extent. Without the use of contrast agents, a single scan provides detailed visualization of microvascular structures in each lesion area, reducing diagnostic burden and enhancing efficiency.

Clinical Insight	A single scan without contrast agents provides precise visualization of microvascular structures in both the superficial and outer layers.

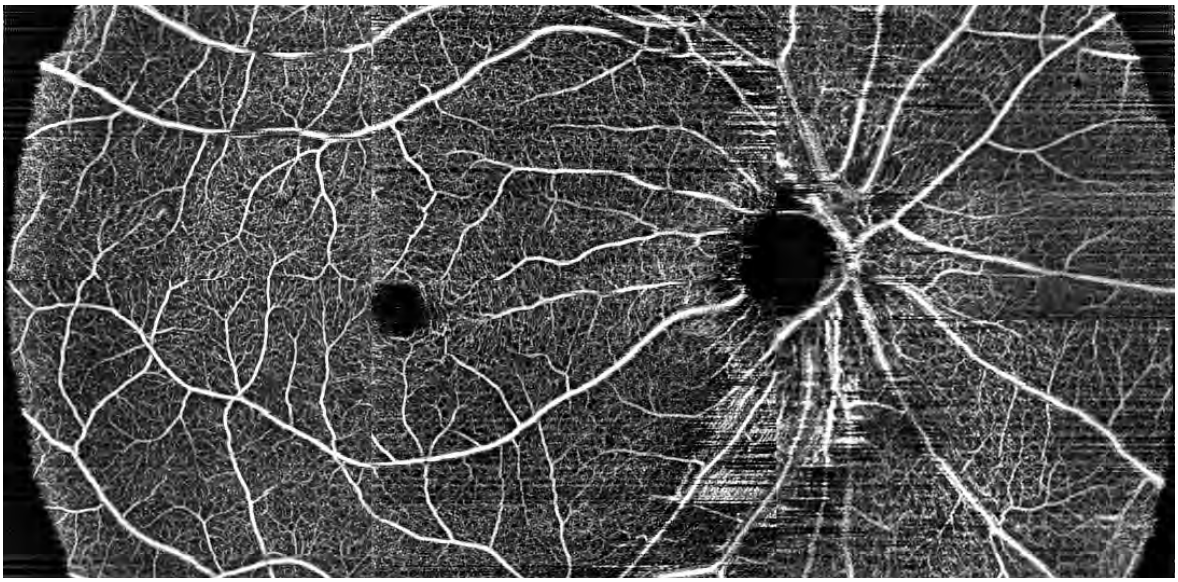

Macular angio 384x384, panorama(3x2), overlap 3, 4.5x4.5mm, superficial, Huvitz

Wide-area vascular topography acquisition

A wide vascular topography, which is difficult to capture with a single shot, can be obtained. Microvasculature in both the central and peripheral areas can be observed simultaneously in a single image, allowing for more precise identification of lesion location, extent, and morphology.

Clinical Insight	Simultaneous diagnosis and monitoring of peripheral retinal lesions.

Topography

Comprehensive Corneal Mapping

The anterior and posterior corneas are precisely analyzed using a total of 16 maps, including elevation maps and pachymetry maps, which aid in diagnosis and surgical planning.

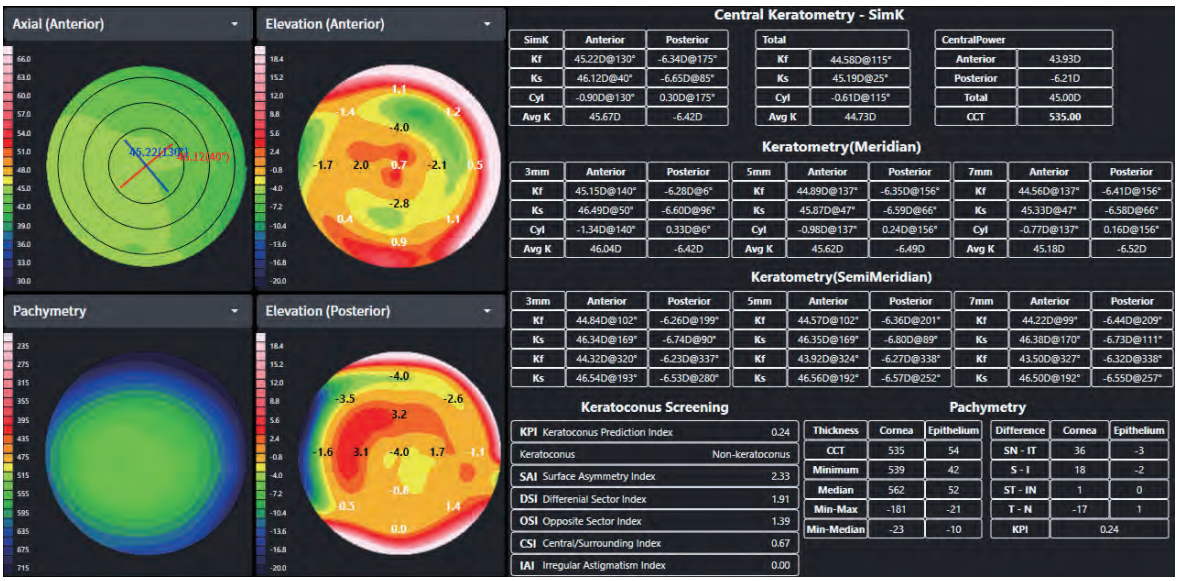

Maps and numerical data viewed on a single screen

On one screen, users can view four maps—Axial Map, anterior and posterior Elevation Maps, and Pachymetry Map—while simultaneously checking key numerical parameters such as SimK, Meridian, Keratoconus index, and retinal epithelial thickness. Users can swap maps or adjust the layout as needed, allowing flexible use tailored to diagnostic purposes and situations.

Clinical Insight Precise lens prescription and corneal/refractive surgery planning.

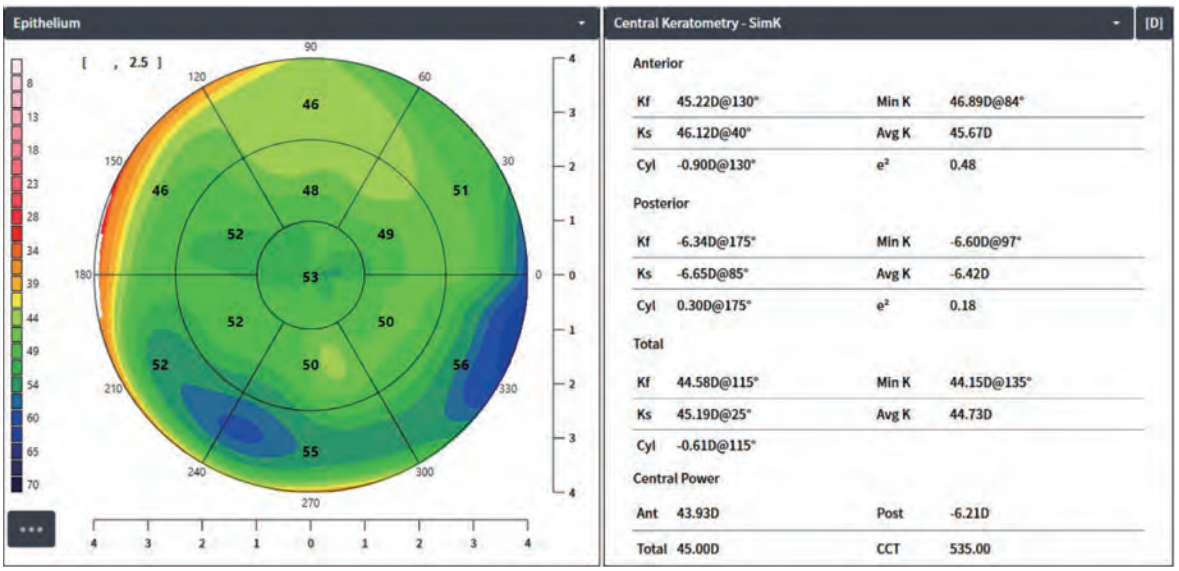

Streamlined clinical workflow

Analysis screens can be printed or sent to a PACS server in DICOM format, facilitating easy storage and sharing of test results. When printing, the background can be switched to white to improve report readability. Integration with hospital EMR and PACS systems further simplifies the clinical workflow.

Clinical Insight Streamlined clinical workflow and easy data sharing through integration with hospital EMR/PACS systems.

Biometry

Accurate IOL Calculation in OCT

With a full anterior segment view, data can be reviewed and adjusted, facilitating customized surgical planning for patients.

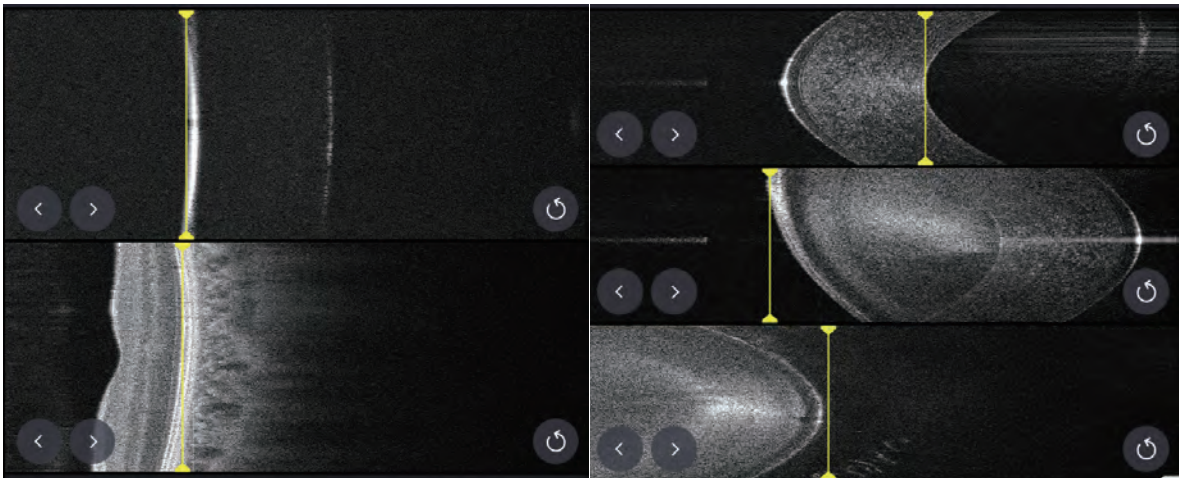

Fast, precise, and highly reliable measurements

Burst Mode performs rapid consecutive measurements—three times for axial length and five times each for central corneal thickness(CCT), anterior chamber depth(ACD), and lens thickness(LT)—to improve data consistency and accuracy. After measurement, B-scan images can be immediately reviewed on the Confirmation screen, allowing fine adjustments if needed. Poor-quality scans caused by blinking or slight eye movement are automatically excluded. This ensures highly reliable IOL calculations and surgical planning, even for patients with severe cataract opacity or macular deformation.

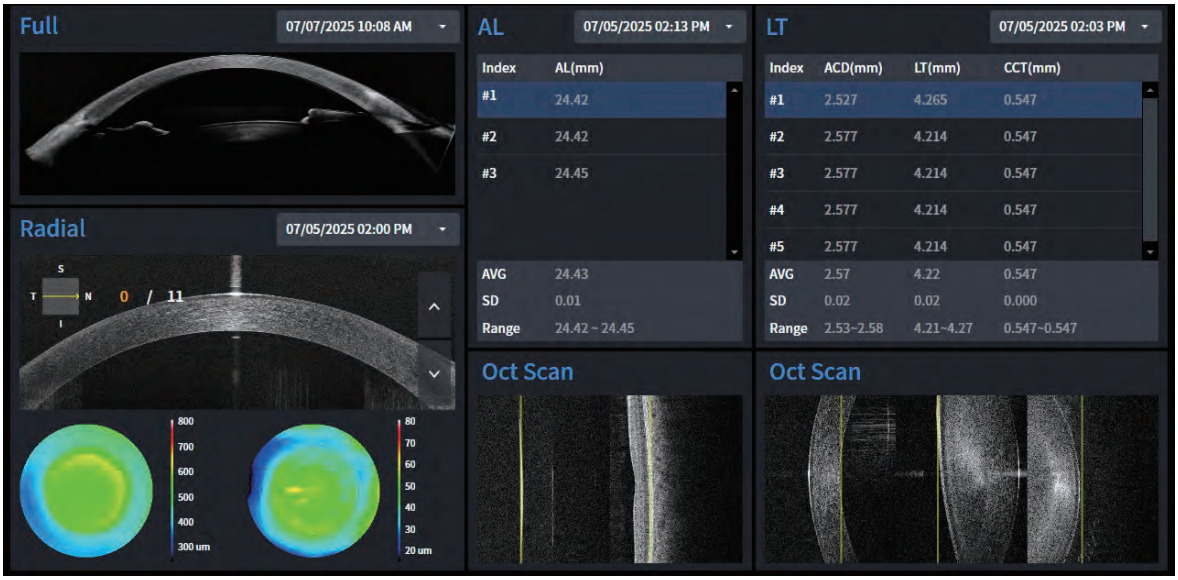

Complete overview from precise measurements to IOL recommendations

The biometry analysis screen includes AL, TL, Radial, and Full Anterior views, offering a three-dimensional understanding of ocular structures from multiple angles. Measurement parameters such as AL(axial length) and TL(lens thickness) can be selectively reviewed, and layer boundaries can be manually adjusted to ensure precise analysis, even in complex anatomical cases. By integrating AL, CCT, ACD, LT, and corneal topography-based K-values, the system can automatically recommend the optimal IOL lens for each patient.

Anterior OCT

Wide Anterior OCT in One Scan

The entire anterior segment—from the corneal angles to the lens—can be examined in a single scan, delivering information optimized for both pre- and post-surgical evaluation and IOL planning.

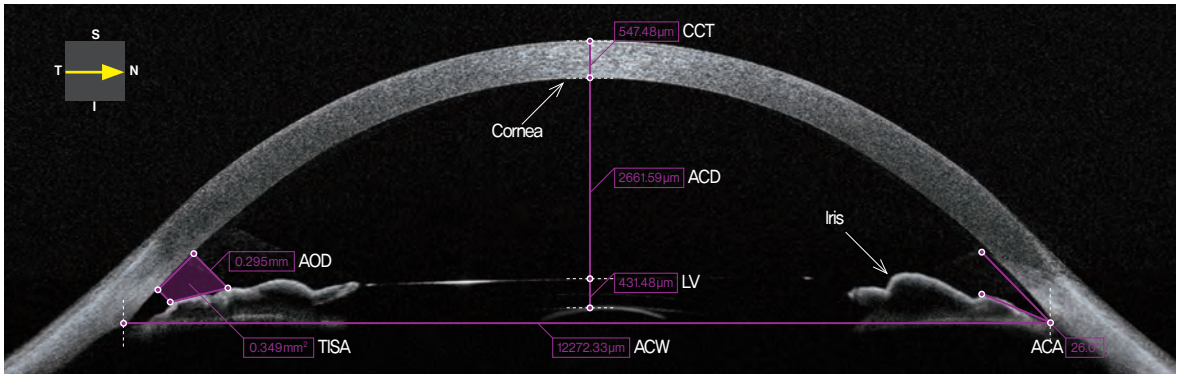

Visualization of the entire anterior segment with Full Anterior imaging

A single scan captures the full structure of the anterior segment—from the cornea to the lens—visualizing the iris and anterior chamber. Key parameters such as White-to-White and ACT are automatically measured, enabling objective comparison and evaluation, from distinguishing between open-angle and angle-closure glaucoma to assessing changes before and after refractive lens surgery.

Clinical Insight	Useful for early detection of anterior chamber angle disorders and pre- and post-operative tracking in refractive lens procedures.

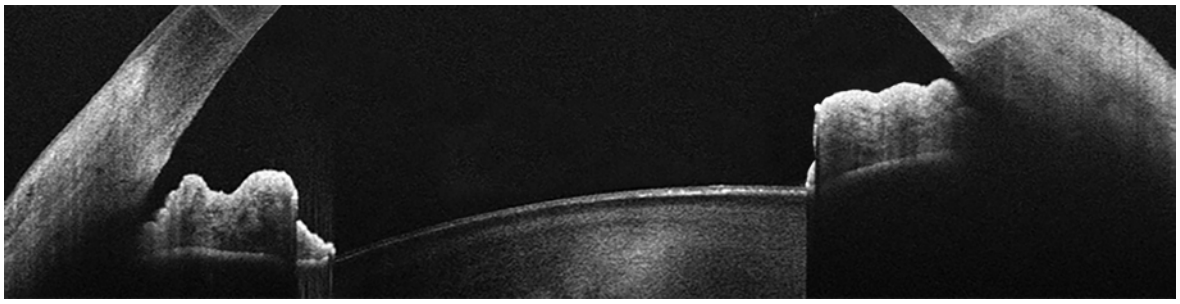

Visualization of the anterior structure of the ciliary muscle and crystalline lens

With the Wide One Line Scanning function, the anterior structure of the ciliary muscle and crystalline lens can be visualized at a glance. This allows for the rapid assessment of changes in ciliary muscle function, as well as the position and shape of the crystalline lens, making it effective for pre- and post-surgical comparisons. It supports anterior segment functional analysis in various clinical contexts, such as presbyopia correction and IOL implantation.

Clinical Insight	Rapid assessment of ciliary muscle function and lens position changes for pre- and post-surgical comparison.



Cornea analysis

Using the Anterior Segment Module, cross-sectional images of the cornea are acquired to precisely measure corneal thickness, curvature, and anterior and posterior structures. These measurements can be visualized and analyzed in both two-dimensional(2D) and three-dimensional(3D) formats.

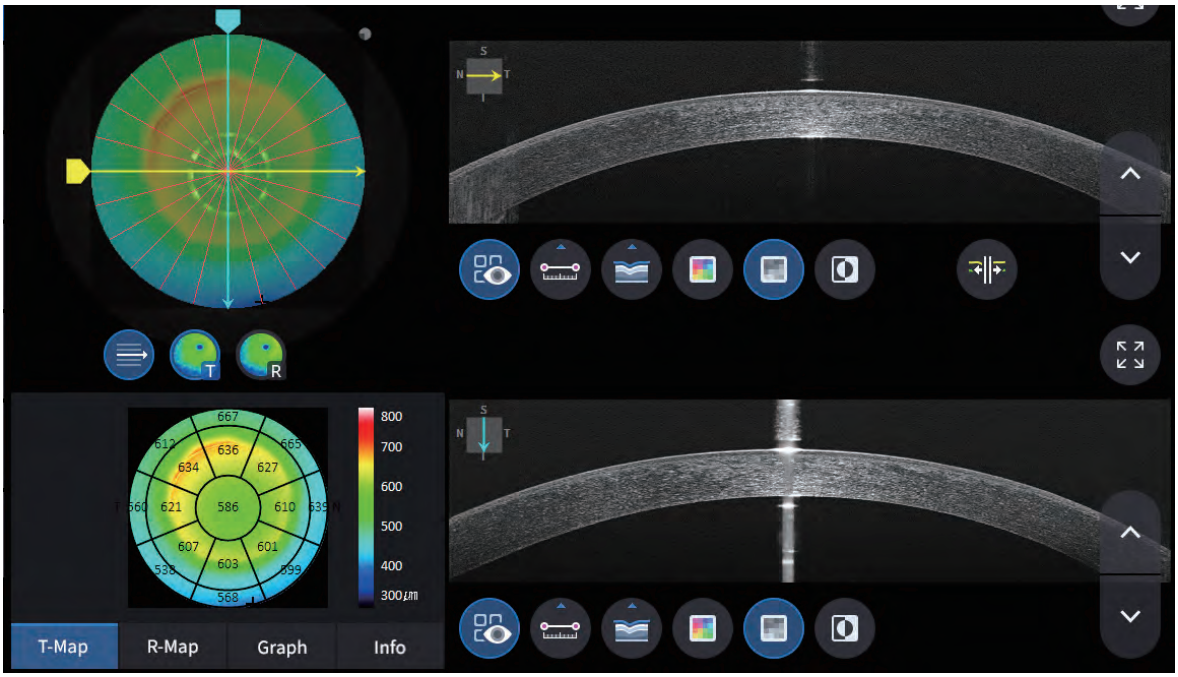

Radial analysis

Using the Corneal Thickness Map, the overall corneal thickness distribution and the thinnest point can be identified. Corneal abnormalities, such as keratoconus, can be detected through the visualized corneal topography.

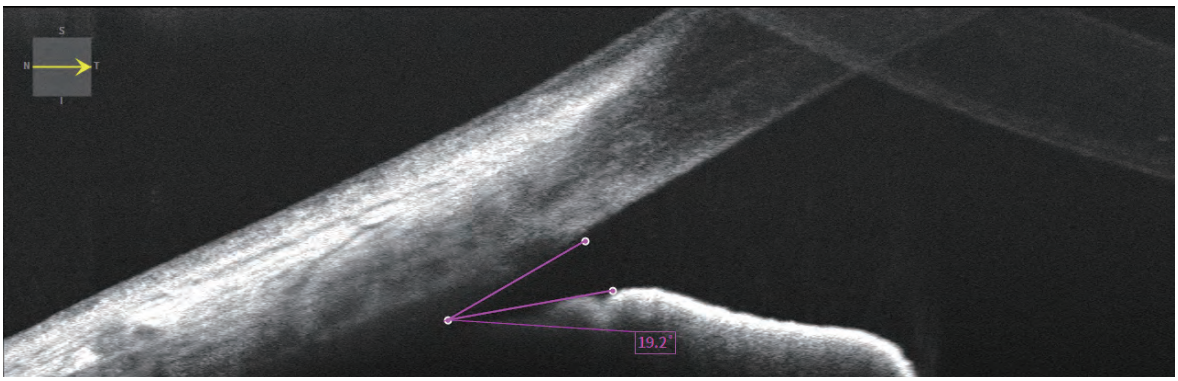

Anterior chamber angle analysis

Using anterior segment cross-sectional images, the anterior chamber angle(ACA) between the cornea and iris is precisely measured to evaluate whether it is open or closed.

HIIS-1 Optional

HIIS–1(Huvitz Integrated Image Server) enables the filing and integrated management of data measured by Huvitz devices.
The data can be accessed in real time on PCs, mobile devices, and tablets, enhancing clinical convenience.

By Patient | By date | By diagnosis | Any devices



Display of HVF visual field test results

The HVF visual field test results are presented in both chart form and numerical data. These can be compared side by side with the patient's Wide 3D scanning results.

Screen customization based on user needs

Users can customize an integrated screen composed of six windows for more convenient data viewing, tailored to their specific needs.
Examples include fundus, OCT, thickness map, ACA, GOC, and CD ratio in the optic disc area for glaucoma.

Myopia Management

Detailed analysis data of key ocular structures—such as axial length(AL), corneal curvature, and spherical equivalent(SPH EQ)—is provided for the assessment of myopia.
This data enables comprehensive monitoring of patient progress and supports personalized management.

Clinic Exams

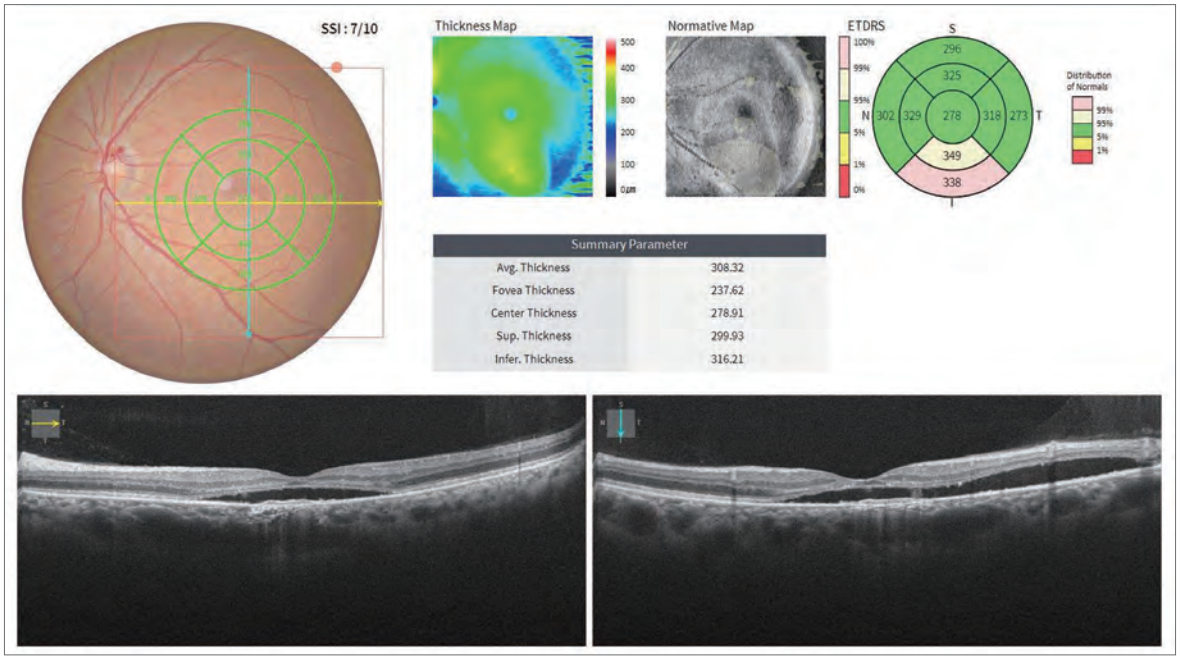

Fundus single macular, level 4, macular 3D 9x9mm, Dankook University

In wet age-related macular degeneration(Wet AMD), choroidal vessel dilation is typically accompanied by hemorrhagic pigment epithelial detachment(PED) and compression of the choroidal capillaries.
Accurate diagnosis using OCT and fundus photography supports the need for intravitreal injection therapy.

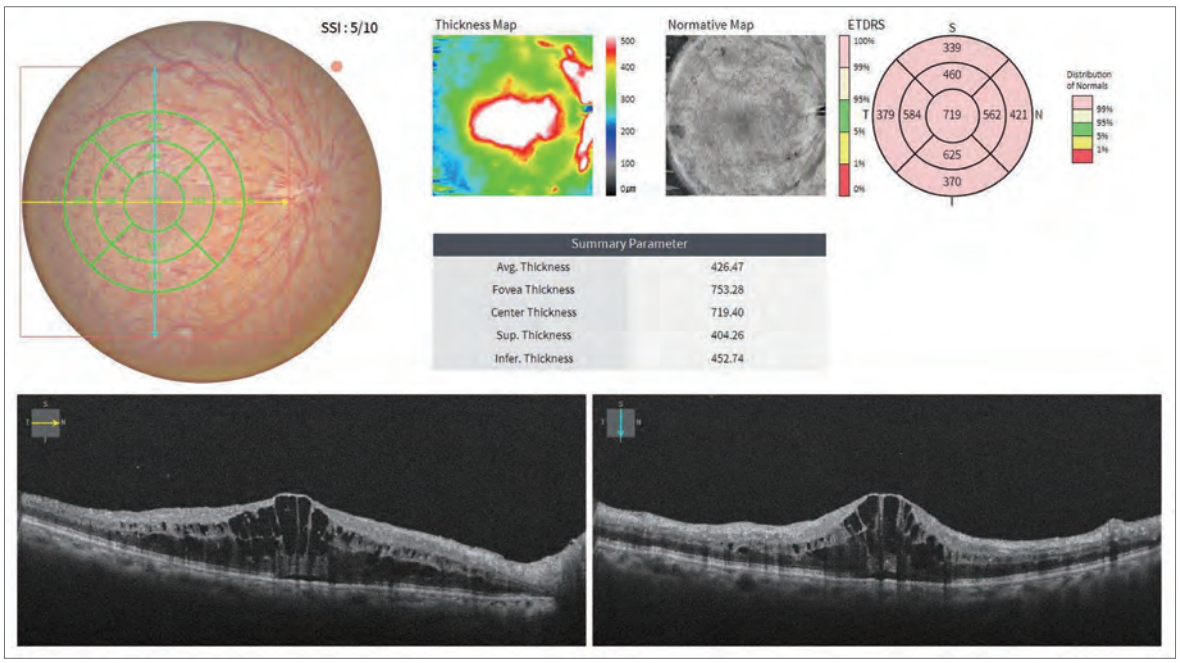

Fundus single macular, level 4, macular cross 9x9mm ,overlap 10, Dankook University

In Central Retinal Vein Occlusion(CRVO), severe macular edema is observed in the central region, accompanied by damage to the inner retinal structure, venous dilation, and hemorrhage. These findings indicate the need for visual acuity testing and fluorescein angiography. Treatment may include intravitreal injection or steroid therapy.

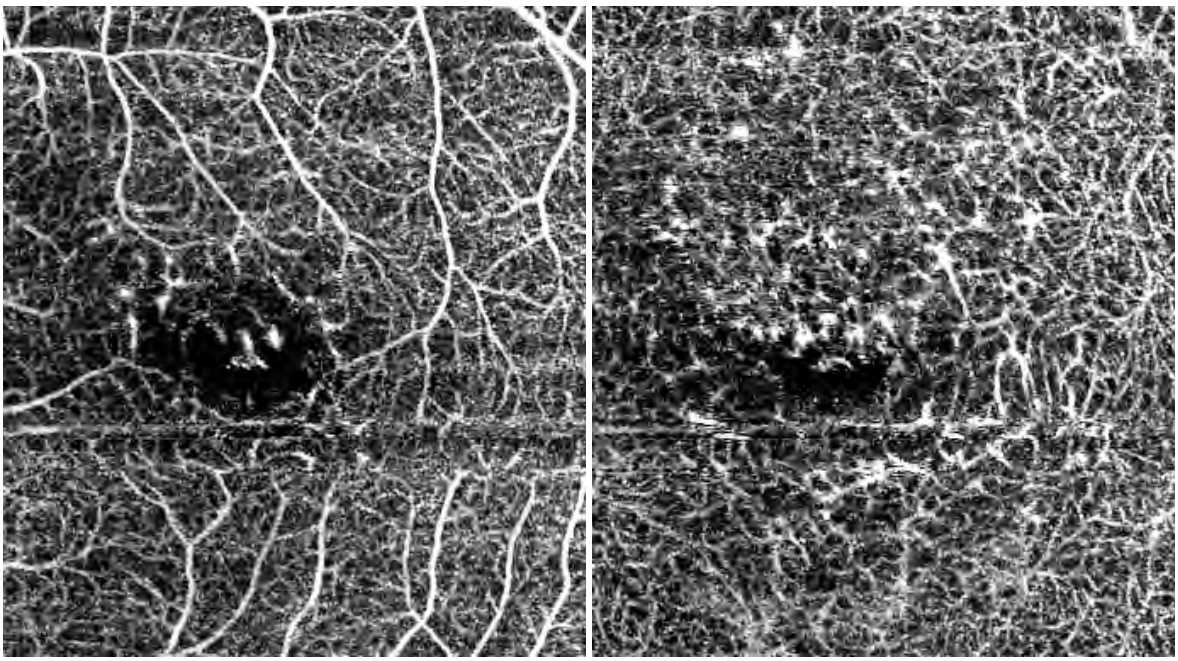

Macular angio 384x384, 3x3mm overlap 3, superficial, Deep, Dankook University

The patient may have non-proliferative diabetic retinopathy(NPDR), as exudates and capillary occlusion are observed. Blood glucose control and intravitreal injection therapy may be required, and prognosis should be monitored through Foveal Avascular Zone(FAZ) analysis and Optical Coherence Tomography Angiography(OCTA).

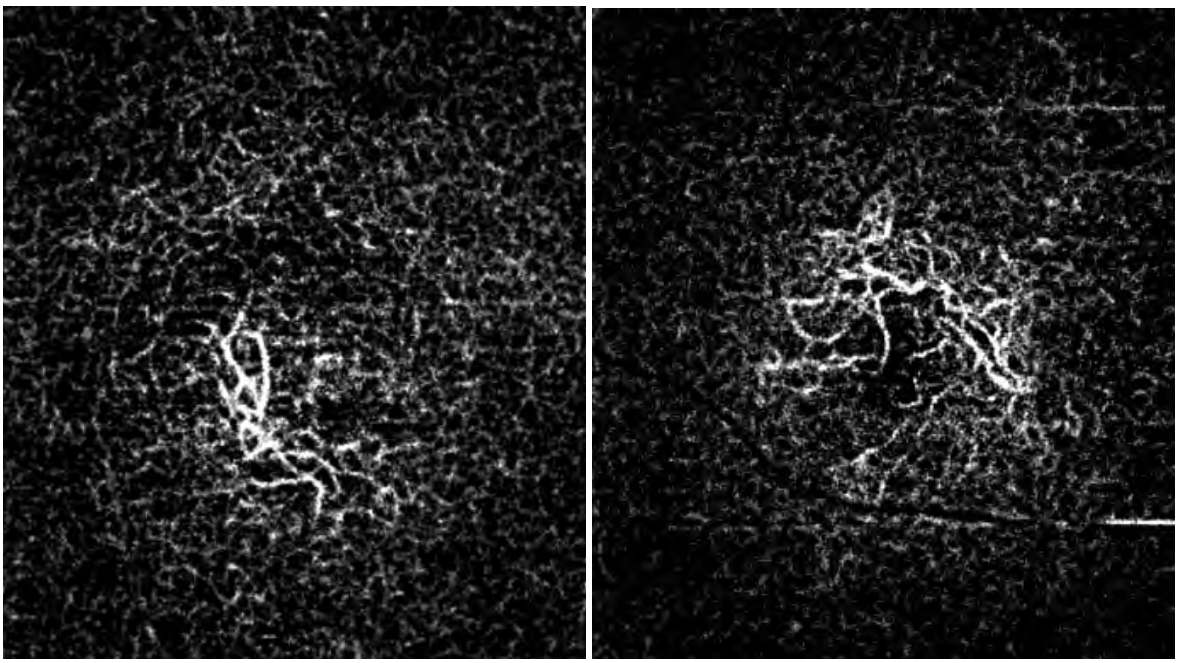

Macular angio 384x384, 3x3mm overlap 3, outer, CNV, Dankook University

Choroidal Neovascularization(CNV) is detected, and Fluorescein Angiography(FA) should be performed to assess neovascular leakage. Treatment includes intravitreal injections or laser photocoagulation, along with regular follow-up monitoring of visual acuity and visual fields.

OCTavius

5-in-1 System for Faster and Deeper Diagnosis
3D OCT, Angiography, Fundus Camera, Biometry, Topography

Specification

OCT	Principle	Spectral domain OCT, Fundus digital photography
	Light source	840 nm
	Scan speed	Max. 80,000 A-Scan/sec.
	Resolution in tissue	20 um (Lateral), 7 um (z-axis) at index 1.36
	Scan Range	X : 6~12 mm, Y : 6~9 mm, Z : 2.34 mm
	Display resolution	X : 5.85 um, Y : 23.40 um, Z : 3.05 um
	Minimum pupil diameter	2.5 mm
	Scan patterns	Macular : Macular Line, Macular Cross, Macular Radial, Macular3D, Macular Raster, Angio (Option) Disk : Disc Circle, Disc Radial, Disc 3D, Disc Raster, Angio (Option)
	Optical power at cornea	≤ 1.3 mW
	Acquisition time of 3D image	1.0 sec (Normal Mode, A512xB96)
	Depth Accuracy (measuring 1 mm glass)	±3%
OCT Angiography *optional(HOCT-1/1F)	Angiography Range	3-9 mm
	Angiography Map	Superficial, Deep, Outer, Choroicapilary, Retina,Custom, Enface, Thickness map, Depth coded map
	Angiography Analysis	FAZ, Vessel Density
Fundus Camera (HOCT-1/1F)	Type	Non-mydriatic fundus camera
	Resolution	60 line pair/mm or more (center) 40 line pair/mm or more (middle) 25 line pair/mm or more (periphery)
	Angle of view	45°
	Camera	Built-in 20M pixel, Color
	Minimum pupil diameter	4.0 mm (Normal mode), 3.3 mm (Small pupil mode)
	Flash light	White light, 10 levels
	Pixel pitch at fundus	3.69 um (20M pixel Color)
	Capture mode	Single, Stereo, Widefield Panorama
Common specification	Working distance	33 mm
	Display	12.1 inch, 1280 x 800 pixel, Touch panel color LCD
	Dioptric compensation forpatient's eye	-33D~+33D total -13D~+13D with no compensation lens +7D~+33D with plus compensation lens -33D~-7D with minus compensation lens
	Fixation target	LCD (internal), White LED (external)
	Fundus illumination light	760 nm
	Horizontal movement	70 mm (back and forth), 100 mm (left and right)
	Vertical movement	30 mm
	Chinrest movement	62 mm (up and down), motorized
	Auto tracking	30 mm (up and down), 10 mm (right and left), 10 mm (back and forth)
	Power supply	AC 100 – 240 V, 50/60 Hz, 1.6 – 0.7 A
	PC	Built in computer
	LCD Tilting Angle	70°
	Dimensions / Mass	330 (W) x 542 (D) x 521 (H) mm / 30 kg
Anterior segment adapter *optional(HOCT-1/1F)	Working distance	15 mm
	Scan range	6 ~ 9 mm (width), 2.3 mm (depth)
	Scan pattern	ACA line, Anterior Radial
	Software Analysis	Corneal Layers, Thickness Map, Thickness, Angle
Wide Anterior segment adapter *optional(HOCT-1/1F)	Working distance	15 mm
	Scan range	16 mm (width), 2.3 mm (depth)
	Scan pattern	ACA line, Anterior Radial, Full
	Software Analysis	Dimension, Angle
Biometry *optional(HOCT-1/1F)	Metric	AL, CCT, ACD, LT
Topography *optional(HOCT-1/1F)	Supported Maps	Axial map, Tangential map, Keratoconus Screening
HIIS-1 *optional	Feature	Web-Based, Multi users can be accessible Progression analysis, Comparison analysis, 3D Analysis

* Specification and design are subject to change without notice.

Huvitz CONNECTING SIGHT SUCCESS
38, Burim-ro 170beon-gil, Dongan-gu, Anyang-si, Gyeonggi-do, 14055, Republic of Korea
Tel : +82-31-428-9100 Fax : +82-31-477-8617 http://www.huvitz.com
W2XXCL-21-00008, 26.02.10, RevE